

# Clinical Benefit of Using a Multifractional Er:YAG Laser Combined With a Spatially Modulated Ablative (SMA) Module for the Treatment of Striae Distensae: A Prospective Pilot Study in 20 Patients

Jean Paul Meningaud, MD, PhD, Mounia SidAhmed-Mezi, PhD, Raphaelle Billon, MD, Kessara Rem, MD, Simone La Padula, MD, and Barbara Hersant, MD, PhD\*

Department of Plastic, Reconstructive and Maxillo facial Surgery, Hopital Henri Mondor, Creteil 94010, France

**Background and Objective:** Striae distensae (SD) are cutaneous lesions that often occur on the breasts, abdomen, hips, and thighs. The aim of this study is to evaluate the effectiveness of a new technique using a non-invasive Er:YAG laser combined with Spatially Modulated Ablation (SMA) module for the treatment of SD.

**Study Design/Materials and Methods:** This prospective pilot clinical study included 20 patients with skin phototypes I to IV who are affected by SD. The Er:YAG 2940 nm laser with SMA module was used in scanning mode with fluences of 2.3 J/cm<sup>2</sup>, frequency of 3 Hz, and pulse duration of 0.3 milliseconds. The laser beam is split into several microspots and penetrates only by 50 μm in the epidermis thickness. This technology induces also the generation of acoustic waves to stimulate tissue regeneration. Each patient underwent six laser sessions. An objective and subjective assessment of SD were used. All adverse events were reported.

**Results:** Most patients reported good improvement and expressed their satisfaction with the treatment. Cutometric analysis showed significant improvement in skin elasticity at the end of study. Moreover, ultrasound analysis revealed an increase in dermal thickness ( $P < 0.01$ ). POSAS scores decreased significantly at 3 and 6 months, reflecting improved skin quality. The average recovery time was 5 days, with no adverse effects reported.

**Conclusion:** Using Er:YAG laser (2,940 nm) with SMA technology to treat SD resulted in improved volume and textural appearance without side effects. The elasticity and thickness of the dermis also improved. The Er:YAG laser with SMA module may be considered as a novel and effective technique to treat SD lesions with minimal time recovery. *Lasers Surg. Med.* © 2018 Wiley Periodicals, Inc.

**Key words:** laser; microablative; Er:YAG; spacially modulated ablative module; striae distensae; stretch marks; RecoSMA; SMA

## INTRODUCTION

Striae distensae (SD), or stretch marks, are dermal scars. Initially SD appears erythematous and purplish in

color (striae rubrae), over time they atrophy and lose their pigmentation to become pearlescent white (striae albae) [1]. This common dermatologic condition causes distress for aesthetic reasons, potentially creating a psychological burden for patients. Stretch marks frequently occur during pregnancy, obesity, rapid weight loss, Cushing's syndrome, or following treatment with topical or systemic corticosteroids [2–4].

From a histological viewpoint, SD are scars with bundles of stretched, atrophied collagen resulting in a loss of around 50% of dermal thickness and elastic fibers [5,6].

It is difficult to remove stretch marks, and to date, few treatment methods have proven to be effective. Various therapeutic approaches are available to treat stretch marks but they have met with limited success in terms of efficacy: tretinoin-based creams are often used to prevent these dermal lesions [7,8] as are hydrating creams [9,10], chemical peels [11,12], microdermabrasion [13,14], radiofrequency devices [15], intense pulsed light [16,17], and needling therapy [18,19].

A number of studies have shown the effect of lasers at different wavelengths to stimulate fibroblasts [20]. Non-ablative laser techniques were used to treat SD including, pulsed-dye laser (PDL) [21], excimer laser [22], the 1064 nm neodymium-doped YAG (Nd:YAG) [23], and the 577 nm copper bromide laser [24]. Improvement in SD after fractional nonablative laser were also reported [25–28]. Ablative lasers were also used to improve the SD, they include the CO<sub>2</sub> laser [29] but this technique presents a risk of hyperpigmentation for dark phototypes [30].

**Conflict of Interest Disclosures:** All authors have completed and submitted the ICMJE Form for Disclosure of Potential Conflicts of Interest and none were reported.

Contract grant sponsor: Linline.

\*Correspondence to: Barbara Hersant, MD, PhD, Department of Plastic, Reconstructive and Maxillo facial Surgery, Hopital Henri Mondor, 51 avenue du Maréchal de Lattre de Tassigny, Creteil 94010, France. E-mail: barbara.hersant@gmail.com

Accepted 3 November 2018

Published online in Wiley Online Library

(wileyonlinelibrary.com).

DOI 10.1002/lsm.23042

A non-ablative fractional laser uses reconstructive Spatially Modulated Ablation (RecoSMA) technology was used in our study. This new, non-invasive technology can be equipped with an erbium-doped yttrium aluminum garnet (Er:YAG) laser operating at a wavelength of 2,940 nm (which allows the absorption of water molecules) and fitted with a specially designed Spatially Modulated Ablation (SMA) nozzle. The laser beam is fractionated into thousands microbeams (around 10,000 per square cm). Each microbeam measures 50  $\mu\text{m}$  in diameter, and they are spaced 50  $\mu\text{m}$  apart. Thus, the advantage of this technology is that the laser induces minimal ablative and thermal effects, since the beam penetrates only 50  $\mu\text{m}$  into the thickness of the epidermis.

Moreover, this technology induces the generation of acoustic waves at depths of 3–6 mm, allowing superficial destruction of the epidermis, leading to tissue regeneration. The superficial absorption of the laser energy by the tissue, as well as the transmission of powerful acoustic waves, cause micro-traumas resulting in very superficial microablation of the epidermis. This is sufficient to remove several layers of epidermal cells without exceeding the thickness of this cutaneous layer, and without generating fibrous tissue, due to the absence of thermal damage [31–33].

Unlike conventional lasers, the RecoSMA technology is a non-fractional, non-thermal method (skin temperature remains stable at 36.6°C and thermal effect is minimal). This method is micro-ablative. The epidermis undergoes minimal damage (50  $\mu\text{m}$  microbeams) and the skin's protective function as a barrier is not compromised, which limits side effects and reduces recovery time, unlike ablative lasers that create a high risk of hyperpigmentation, particularly among dark-skinned patients [34,35]. The histological results using this technology highlighted changes in the thickness of the epidermis, with an increase in newly formed collagen fibers observed below the epidermal-dermal junction. Neovascularization was also observed [31].

The aim of this treatment is to stimulate the fibroblasts and improve or restore skin quality in the areas affected by stretch marks. The body's reaction to these micropunctures is cellular stimulation and regeneration, which results in the restructuring of newly formed collagen and elastin fibers. Our aim with this prospective pilot study was to provide an objective and a subjective assessment of the efficacy and tolerance of the 2,940-nm Er:YAG RecoSMA laser for the treatment of stretch marks among a patient population representing a range of Fitzpatrick skin phototypes.

## MATERIALS AND METHODS

### Study Design and Patients

This monocentric prospective clinical study was conducted in the Plastic Surgery Department of Henri Mondor Hospital (Créteil, France). Between April 2015 and March 2016, we enrolled and treated a total of 20 patients presenting stretch mark scars of various stages of

maturity, based on the Deprez–Adatto classification of stretch marks: stages I, IIa, IIb, IIIa or IIIb, and IV [36].

Based on a 20% effect size for the Er:YAG laser + SMA (RecoSMA), a 5% bilateral alpha risk, and an 80% beta risk, it was determined that 18 patients were necessary for this study. Based on a 10% loss to follow-up or non-evaluable data, we included 20 patients in the study. Pregnant and breastfeeding women and women who had undergone treatment for stretch marks in the previous 6 months were excluded from the study. We also excluded patients with scarring disorders (hypertrophic scarring and keloids), a history of skin cancer, patients with a heart pacemaker or metallic implant, as well as patients with an inflammatory disease and those with vitiligo. All patients signed a written informed consent form.

### Treatment With Er:YAG Laser Combined With RecoSMA Technology

Prior to treatment, the area to be treated was disinfected with chlorhexidine solution. No anesthesia was used.

Patients received treatment with the Multiline™ Er:YAG laser (device manufactured by LINLINE Medical System, Minsk, Belarus) combined with RecoSMA technology.

The device was attached to a hand-piece in the beam output window. The RecoSMA module ensured the necessary spatial distribution of laser beam energy. Treatment was performed in scanning mode with the following dose: 2.3 J/cm<sup>2</sup> (deep RecoSMA) with a frequency of 3 Hz and pulse duration of 0.3 microseconds. One site per patient was treated (either *abdomen* or *buttock* or *thigh* or *lower back*). When SD is bilateral, both sides were treated. Each patient received six laser sessions, which took place at 1-month intervals.

### Objective Assessment

All measurements were made in the same area of SD. Before the first treatment session, we tattoo the area of SD where the measurements will be made. For others treatment sessions and the follow-up, we checked the picture took the first time to perform the measurements (ultrasound and elasticity) and take the pictures at the same area where SD are located. For skin elasticity and ultrasound measurements we take the mean of two measurements when SD is bilateral.

**Measuring skin elasticity.** The mechanical properties of the skin were determined using a non-invasive suction device to measure skin elasticity (Cutometer® MAP580, Courage and Khazaka Electronic GmbH, Cologne, Germany). We used a 2 mm diameter measuring probe and applied constant suction at 450 mbar for 1 second, following by 1 second of relaxation, repeated three times. We took measurements at the start of treatment, as well as 3 and 6 months after the final laser treatment session.

Using the cutometer software, we calculated the mechanical parameters: R2, R5, R6, and R7. R2 refers to gross elasticity. R5 refers to the net elasticity in the absence of viscous deformation, calculated by the

“immediate retraction”/“immediate distention” ratio  $R5 = U_r/U_e$ , where a value close to one (100%) indicates very elastic skin.  $R6$  represents the portion of viscoelasticity on the elastic part of the curve, represented by the “viscoelastic”/“elastic distention” ratio:  $R6 = U_v/U_e$ . Since the parameter  $R6$  measures the skin’s stretching capacity, negative values reflect improved skin condition.  $R7$  refers to recovery after deformation; this is the portion of elasticity compared to the final distention. It is calculated using the “immediate retraction”/“final distention” ratio:  $R7 = U_r/U_f$ , where a value close to one (100%) indicates very elastic skin.

**Ultrasound assessment.** Assessment based on ultrasound images was carried out using the Dub<sup>®</sup>cutis skin scanner system (Taberna pro medicum, Lüneburg, Germany), a high-resolution ultrasound system with a 22 MHz transducer able to monitor depths of up to 6–7 mm, including the epidermis, the dermis and part of the subcutaneous adipose tissue. We performed ultrasound assessment before starting treatment and 6 months after the last laser session.

### Subjective Assessment

**Photographs.** Photographs were taken using a Canon DS126231 camera with a macrophoto lens before starting treatment and after each treatment session, as well as at 6 months (end of study).

**Patient and observer scar assessment scale (POSAS).** The Patient and Observer Scar Assessment Scale (POSAS) was used to evaluate the skin quality of stretch marks prior to treatment and at the end of the study. The POSAS score is the combined total of all scores obtained using two scales: the Patient Scar Assessment Scale (PSAS) and the Observer Scar Assessment Scale (OSAS). The POSAS scale was performed by blinded physician assessor in the presence of patient [37].

**Patient satisfaction scale.** Improvement in the appearance of stretch marks was measured using a 5-item Likert scale: no improvement, slight improvement, moderate improvement, good improvement, and very good improvement of the stretch mark scar [38].

### Evaluating Tolerance

Any pain during treatment was assessed using the Visual Analog Scale (VAS from 1 to 10). Side effects and potential complications were recorded at each visit.

### Follow-Up Visits

Two follow-up visits were scheduled with patients: one at 3 months and another 6 months after the final treatment session.

### Statistical Analysis

We used PRISM, version 5 (GraphPad Software, La Jolla, CA) to analyze the elasticity values of the different parameters and the thickness of the dermis based on ultrasound assessment. Fluctuations in the percentage of the different parameters were determined using the

following equation: percentage of change =  $[(a - b)/b] \times 100$ , where “ $a$ ” was the individual value of  $R5$ ,  $R6$ , or  $R7$  at 6 months and “ $b$ ” was the corresponding zero-time (before treatment). The Student’s  $t$ -test was used to compare the mean values.  $P < 0.05$  was considered to be statistically significant. The Tukey test was used for many different comparisons.

## RESULTS

### Clinical and Demographic Characteristics of Patients Enrolled in the Study

Table 1 presents demographic information about study participants. We enrolled 20 patients to take part in this study. Study participants were aged from 21 to 58 years, with a mean age of  $35.7 \pm 11.47$ . The mean BMI was  $23.73 \pm 3.49$ . The patient population was 85% white (Caucasian), 10% North African, and 5% African. The Fitzpatrick skin phototypes of participants included: phototype I, 30%; phototype II, 25%; phototype IV, 25%; phototype III, 10%; and phototype VI, 10% (Table 1).

Study participants underwent treatment for stretch marks at various stages of maturity and located at different sites on the body. Of the SD that were treated, 50% were on the abdomen; 30% on the buttocks; 10% on the lower back; and 5% on the thighs (Table 1). Each patient was treated on a single area of the SD example: *abdomen* or *buttock* or *thigh* or *lower back*. In the case where the stretch mark is bilateral, both sides were treated.

According to the Deprez–Adatto classification of stretch marks, 40% of the patients’ stretch marks corresponded to stage IIb (white, superficial striae without rung but with palpable depression at the surface of the skin); 20% to stage IIIa (white, atrophic striae with rung measuring less than

**TABLE 1. Demographic and Clinical Data of Patients Included in the Study**

	Number (%)
Phototype	
I	6 (30)
II	5 (25)
III	2 (10)
IV	5 (25)
VI	2 (10)
Distribution of SD	
Abdomen	10 (50)
Buttocks	7 (30)
Lower back	2 (10)
Thigh	1 (5)
Type of SD	
1	1 (5)
2a	2 (10)
2b	8 (40)
3a	4 (20)
3b	4 (20)
4	1 (5)

SD, striae distensae.

1 cm in width, without pearly aspect at the depth); 20% to stage IIIb (white, atrophic striae with rung measuring less than 1 cm in width, with pearly aspect at the depth); 10% to stage IIa (white, superficial striae without rung and without palpable depression); 5% to stage I (fresh, inflammatory, usually purple striae); and 5% to stage IV (white, atrophic striae with rung measuring more than 1 cm in width, with pearly aspect at the depth) (Table 1).

The maturity of stretch marks (i.e., the time since they first appeared) ranged from 2 to 32 years, with an average of 13 years  $\pm$  9.19. The causes were pregnancy in 60% of cases, weight variation in 30% of cases, and puberty in 10% of cases.

### Results of Objective Assessments

**Analysis of skin elasticity using the cutometer.** The results of biomechanical analyses of the skin showed significant improvement in elasticity and firmness parameters (Table 2). Improvement in gross elasticity (R2) reached 6.4%; net elasticity (R5) improved by 32.7%; viscoelasticity (R6) improved by 24.4%; and a 14% improvement in R7 (biological elasticity) was shown 6 months after treatment (Fig. 1).

The average value of R2 parameter (gross elasticity) had increased significantly compared to baseline (before treatment), going from  $0.8177 \pm 0.073$  to  $0.961 \pm 0.033$  at 3 months ( $P < 0.0001$ ) and  $0.962 \pm 0.031$  at 6 months ( $P < 0.0001$ ). Similarly, the mean value of net elasticity (R5) had significantly increased at 3 months ( $0.749 \pm 0.107$  before treatment and  $0.898 \pm 0.115$  at 3 months,  $P < 0.0001$ ) and 6 months ( $0.749 \pm 0.107$  before treatment and  $0.995 \pm 0.091$  at 6 months,  $P < 0.0001$ ). The average of R6 parameter (measuring the portion of viscoelasticity) had significantly decreased at 3 months ( $0.481 \pm 0.1004$  before treatment and  $0.366 \pm 0.118$  at 3 months,  $P < 0.006$ ) and at 6 months ( $0.481 \pm 0.1004$  before treatment and  $0.364 \pm 0.021$  at 6 months,  $P < 0.004$ ), thus showing an improvement in skin elasticity that corresponds to the viscoelastic distention/elastic distention ratio. The mean value of R7 parameter, which corresponds to biological elasticity (relaxation phase), had significantly improved at

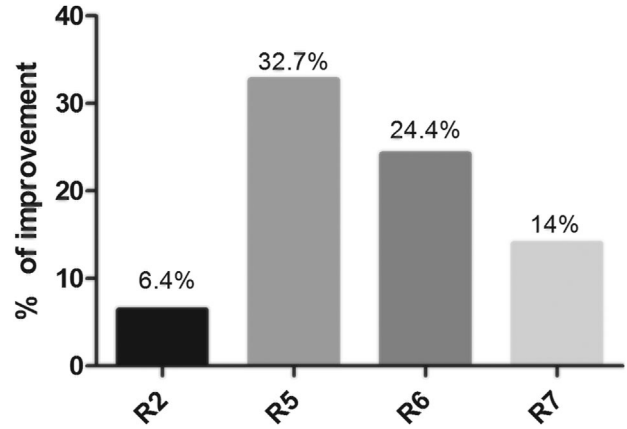


Fig. 1. Percentage of improvement in skin elasticity parameters 6 months after laser treatment. R2 (gross elasticity), R5 (net elasticity), R6 (viscoelasticity ratio), and R7 (biological elasticity).

3 months ( $0.510 \pm 0.09$  before treatment and  $0.621 \pm 0.016$ ,  $P < 0.009$ ), and this improvement continued at 6 months ( $0.510 \pm 0.09$  before treatment and  $0.611 \pm 0.167$  at 6 months,  $P < 0.03$ ) (Fig. 2 and Table 2).

**Ultrasound analysis.** Figure 4 shows two ultrasound images, comparing the skin affected by stretch marks prior to treatment (A) and 6 months after the last treatment session (B). Ultrasound examination of the skin after treatment revealed new echogenic areas at the site of the stretch marks, as well as improved acoustic homogeneity of the dermis (Fig. 3).

We measured the thickness of the dermis (in scanning mode) of all patients before treatment and at the end of the study (Fig. 4). The results showed a significant increase in the average value of the dermal thickness from  $1,065.65 \pm 360 \mu\text{m}$  before treatment to  $1,291.43 \pm 221.45 \mu\text{m}$  at the end of the study ( $P < 0.01$ ).

### Results of Subjective Assessments

**POSAS analysis.** Analysis of the mean of patient POSAS score (PSAS) revealed significant improvement in skin quality and texture of SD at 3 months ( $26.1 \pm 9.0$

**TABLE 2. Tukey's Multiple Comparison Test: Parameters of Elasticity Before Treatment and at 3 and 6 Months After Treatment**

Tukey's multiple comparisons test	Mean Diff.	95.00% CI of diff.	Summary	Adjusted <i>P</i> -value
R2:Before treatment vs. R2:3 months	-0.1439	-0.24 to -0.04784	****	<0.0001
R2:Before treatment vs. R2:6 months	-0.1443	-0.2404 to -0.04819	****	<0.0001
R5:Before treatment vs. R5:3 months	-0.1485	-0.2446 to -0.0524	****	<0.0001
R5:Before treatment vs. R5:6 months	-0.2452	-0.3413 to -0.1491	****	<0.0001
R5:3 months vs. R5:6 months	-0.09672	-0.1928 to -0.0006336	*	0.0469
R6:Before treatment vs. R6:3 months	0.1142	0.01816 to 0.2103	**	0.0063
R6:Before treatment vs. R6:6 months	0.1172	0.02112 to 0.2133	**	0.0043
R6:3 months vs. R6:6 months	0.002967	-0.09312 to 0.09905	ns	>0.9999
R7:Before treatment vs. R7:3 months	-0.1109	-0.2069 to -0.01476	**	0.0096
R7:Before treatment vs. R7:6 months	-0.1007	-0.1968 to -0.004614	*	0.0308
R7:3 months vs. R7:6 months	0.01015	-0.08594 to 0.1062	ns	>0.9999

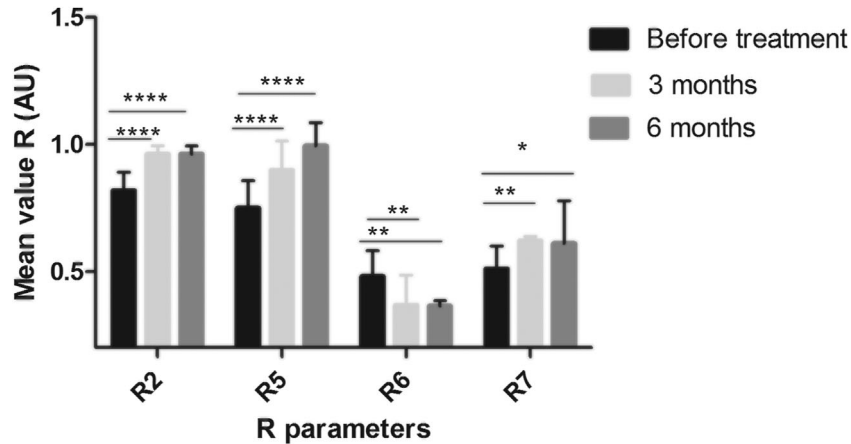


Fig. 2. Characterization of skin elasticity. Values of R2 (gross elasticity), R5 (net elasticity), R6 (viscoelasticity ratio), and R7 (biological elasticity) parameters at baseline, 3 and 6 months after laser treatment (mean  $\pm$  standard deviation, \* $P < 0.05$ , \*\* $P < 0.01$ , \*\*\* $P < 0.0001$ ).

before treatment and  $13.0 \pm 4.3$  3 months after treatment,  $P < 0.0001$ ) and 6 months ( $26.1 \pm 9.0$  before treatment and  $12.85 \pm 2.34$  at 6 months after treatment,  $P < 0.0001$ ). Moreover, the results of the mean of observer POSAS score (OSAS) also indicated significant improvement in skin quality at 3 months: from  $28.5 \pm 9.5$  before treatment to  $12.2 \pm 4.9$  3 months after treatment ( $P < 0.0001$ ). At 6 months, the score had also improved significantly (from  $28.5 \pm 9.5$  before treatment to  $12.85 \pm 3.71$  at 6 months ( $P < 0.0001$ )) (Figs. 5 and 6).

**Analysis of patient satisfaction.** In terms of patient satisfaction, 70% of study participants reported good improvement of SD scars, expressing satisfaction; 15% very good improvement; 10% moderate improvement; and only 5% slight improvement. No patients reported zero improvement (Fig. 7). The patients who had moderate and slight improvement had phototype I, the SD were located in the *abdomen* and the causes of the apparition of SD is the pregnancy. For the one who had noticed slight improvement, the maturity of SD was of 21 years and the stage of SD according to the Deprez–Adatto classification was IV. For the two patients who noticed moderate improvement, the stage of SD was IIIb and the maturity of the SD was of 32 years for one and for the other one it was 20 years.

No complications or undesirable side effects were reported during this study. In the period immediately following a session, edema, and hyperemia occurred 5–10 minutes after treatment. The average recovery period after a treatment session was 4 days. Patients described pain during treatment as tolerable, with an average of  $3.95 \pm 0.32$  on the visual analog scale (VAS).

## DISCUSSION

A large portion of the global population is affected by stretch marks, which represent a psychological burden for many people. Despite the different therapeutic approaches that are currently available, treating stretch marks

remains a challenge. Numerous methods have been put forward, but results have been uneven [39]. Our prospective pilot study appears to show a positive effect after six treatment sessions using the Er:YAG RecoSMA laser with a wavelength of 2,940 nm. The advantage of this technology is that the laser induces minimal ablative and thermal effects, since the beam penetrates only 50  $\mu\text{m}$  into the thickness of the epidermis.

The results of our study pointed to improvement in stretch marks for all patients: improvement of both texture and color, with a significant increase in dermal thickness as well as substantially increased skin elasticity. Measurements of viscoelasticity showed that SD scars were significantly less firm, less elastic, and less deformable than normal skin [40].

Treatment with the multi-fractional RecoSMA laser thus brought about significant improvement of skin elasticity and firmness compared to the results of the various cutometric parameters analyzed prior to treatment of stretch marks. A larger patient cohort and a control group would provide validation of the promising results of our study.

Several nonablative wavelengths including the 1410, 1540, 1450, and 1565 nm lasers have been trialed in the treatment of SD [41–43]. However, results have varied significantly, ranging from moderate improvement to no improvement, and side effects, such as significant erythema and PIH have been reported with these modalities, especially in patients of darker skin types [30,43].

In our patient population, five skin phototypes were represented: 10% of patients had phototype III; 10% phototype VI; 25% phototype IV; 30% phototype I; and 25% phototype II. The RecoSMA laser thus demonstrated its efficacy for both clear and dark phototypes, without causing hyperpigmentation adverse effects.

Few studies have assessed the efficacy of the 2,940 nm Er:YAG laser for the treatment of stretch marks. A study by Gungor et al. compared the efficacy of a 1,064-nm

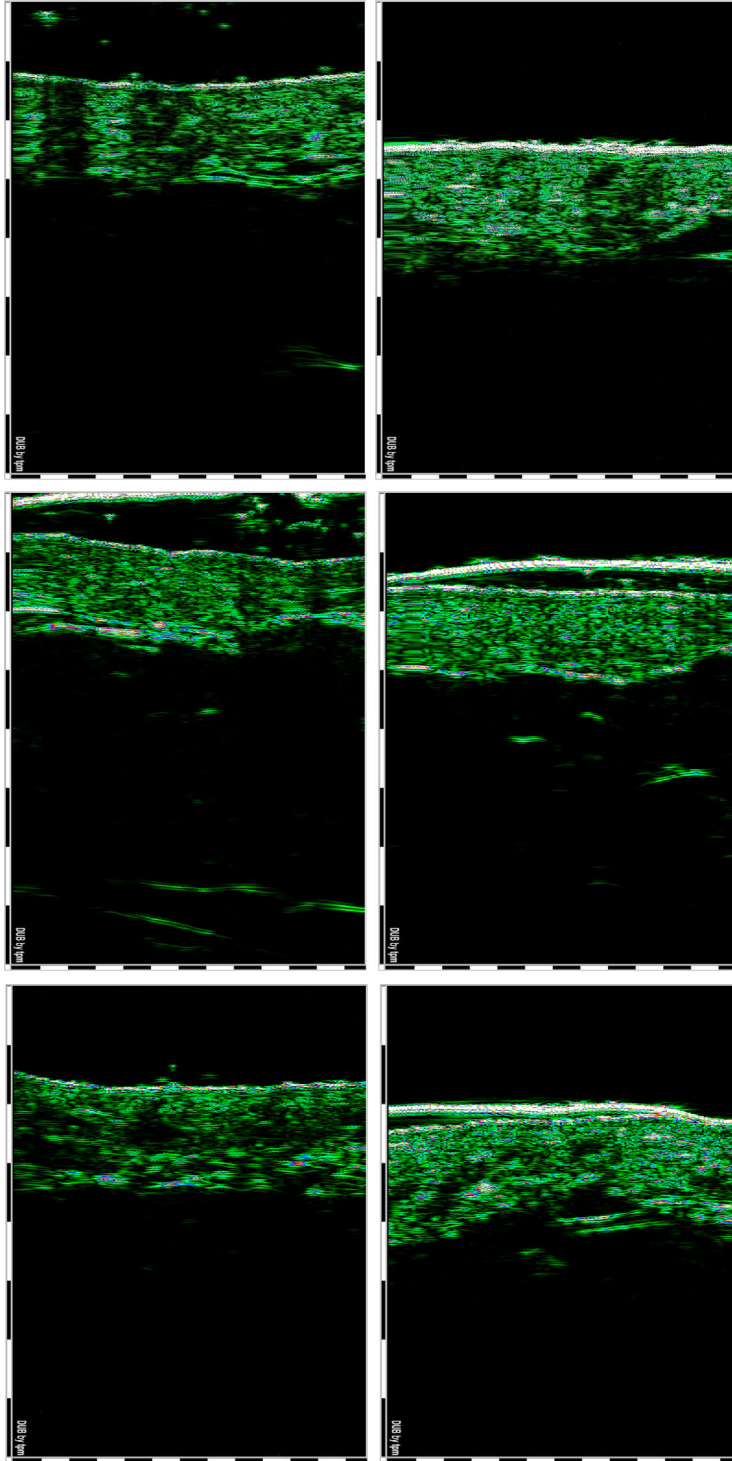


Fig. 3. Ultrasonographic aspect of SD before laser treatment (**left**) and 6 months after treatment (**right**), 22 MHz transducer, B-scan. Ultrasound investigation of the skin revealed the reduction of hyperechogenic areas of the dermis and the improvement of dermis density (it indicates some increasing structural elements, indirectly the number of collagen fibers).

long-pulse laser and the 2,940-nm Er:YAG variable-pulse laser in 20 patients affected by mature and immature stretch marks. Patients received three treatment sessions each month. The clinical results, based on photographic

comparisons, revealed moderate improvement in the appearance of stretch marks among patients with immature stretch marks, but patients with mature stretch marks showed no improvement. Histological results

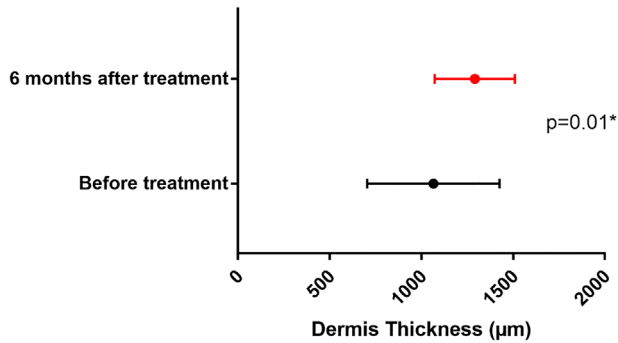


Fig. 4. Ultrasound dermis thickness assessment. Statistical analysis highlighted a significant increase in dermis thickness at the end of the study (6 months). Relative changes in dermis thickness values during the study (mean  $\pm$  standard deviation).

indicating a slight increase in elastic fibers were reported [44]. These findings suggest that three treatment sessions are probably not sufficient to improve the appearance of stretch marks, particularly mature ones that are difficult to treat.

Two other studies have reported positive effects using the 2,940-nm Er:YAG laser. Gauglitz et al. conducted a study on two cases of axial stretch marks, showing that the 2,940-nm Er:YAG laser improved the texture and color in the two cases of mature and immature stretch marks after three and five treatment sessions [45].

The second study, published recently, assessed the efficacy of using the 2,940-nm Er:YAG laser combined with light-emitting diode-red light (LED-RL) treatment and an application of recombinant fibroblast growth factor (FGF) among 30 patients for the treatment of stretch marks located on different parts of the body. Patients received six treatment sessions at 4-week intervals, then

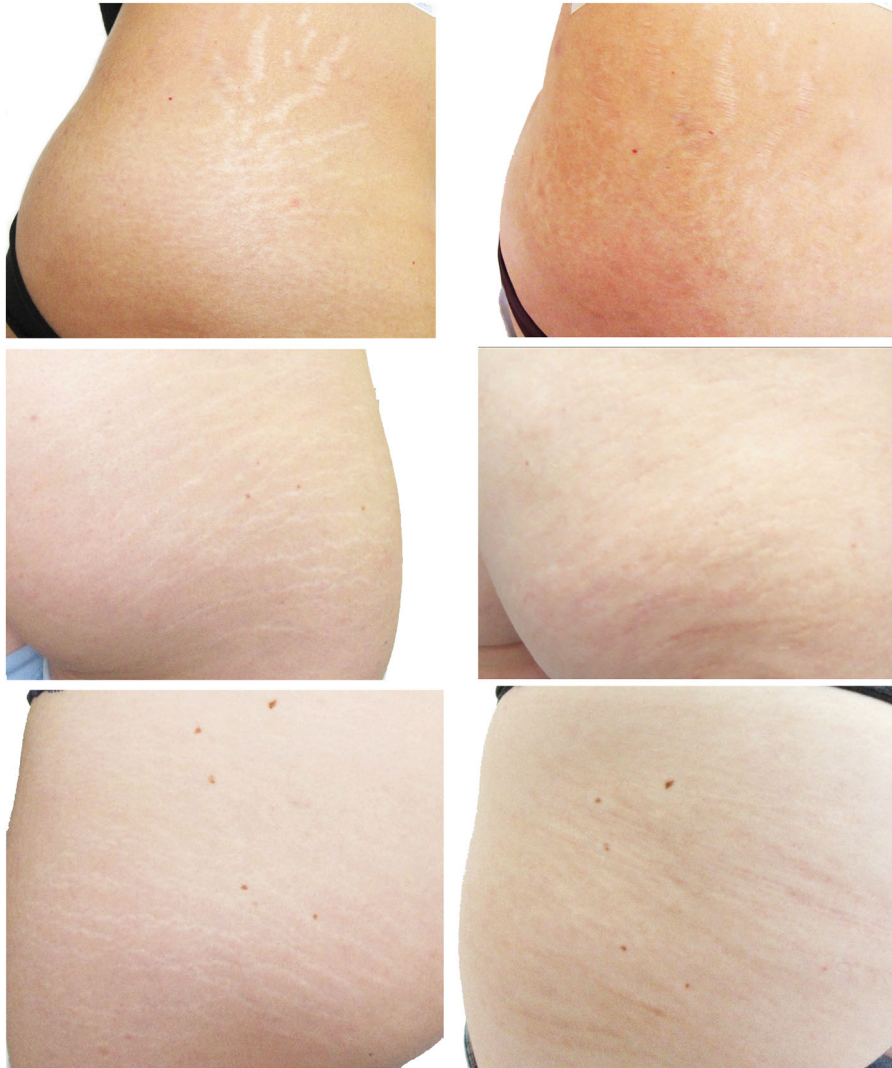


Fig. 5. Photographs Striae distensae before (**left**) and 6 months after treatment (six sessions total) (**right**). An improvement in texture, depression, and color of SD are noted.

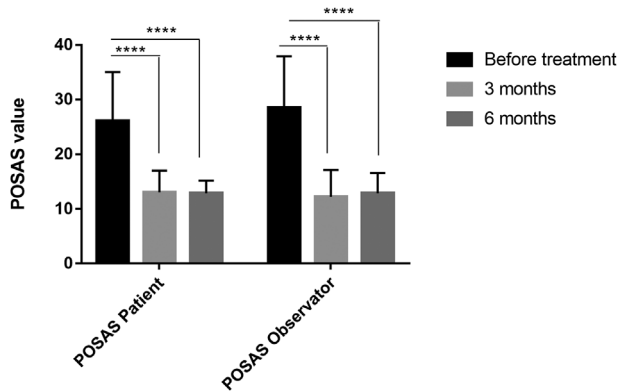


Fig. 6. Patient and Observer Scar Assessment Scale (POSAS) score. The scar quality assessed 3 and 6 months after the last treatment session showed significant improvement compared to baseline (before treatment). Values represent mean  $\pm$  standard deviation. \*\*\*\* $P < 0.0001$ .

FGF applications for 1 week, followed by three LED-RL sessions. This approach resulted in improvement of stretch mark among all patients. Histological results showed an increase in epidermal and dermal thickness, as well as elastin density [46].

These findings agree with the results of our study, which showed that a significant improvement in stretch marks is observed after six laser sessions without adverse events and by reducing time to recovery. Therefore, the Er:YAG laser combined with the SMA technology have many advantages over conventional lasers including less risk of side effects, less discomfort, less recovery time, and no anesthesia is necessary.

Most of the patients (85%) noticed improvement in their stretch marks and expressed satisfaction with the treatment and only 15% noticed moderate and slight

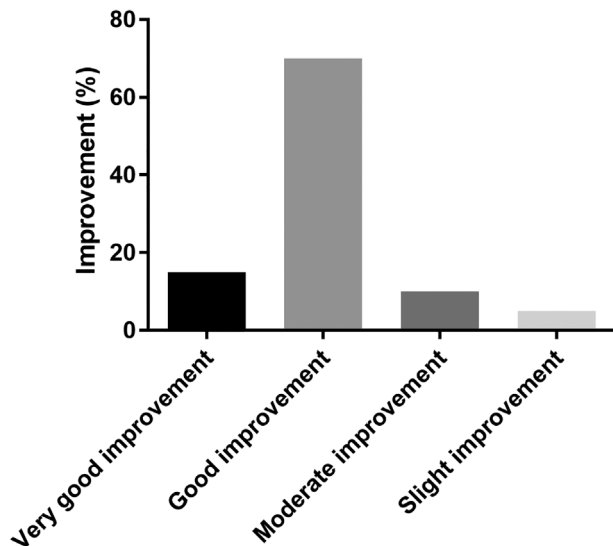


Fig. 7. Evaluation by patients of the improvement in SD, 6 months after the last treatment session.

improvement. For this last group, we notified that the stage of SD was IIIb or IV and the maturity of stretch marks was between 20 and 32 years. Thus, we believe that it would be necessary to consider the stage and the maturity of SD to treat efficiently the stretch marks by increasing for example the number of treatment sessions or decrease the interval of treatment. Unfortunately, the smaller size of the sample did not allow us to perform a multivariate analysis to determine if there is a correlation between the treatment effect and the factors including: maturity of SD, the stage and the location of SD. Further larger and randomized studies might be needed to establish the optimal number of sessions and treatment interval to enhance treatment efficacy.

Otherwise, the histological analysis of stretch marks before and after treatment would have been useful; however, biopsies are too invasive, particularly in the field of aesthetic medicine. Confocal laser microscopy [46,47] has become the instrument of choice to perform optical biopsies but the challenge with this technique is its cost and steep learning curve.

## CONCLUSION

Our prospective pilot study appears to show the efficacy of the RecoSMA laser combined with good tolerance for the treatment of various types of stretch marks in patients with different skin phototypes, with significant improvement of skin texture and quality assessed using objective, non-invasive tools. A randomized controlled study is necessary to validate these results.

## ACKNOWLEDGMENT

Mounia SidAhmed-Mezi received a grant from Linline to follow her research.

## References

- Amaguchi K, Suganuma N, Ohashi K. Quality of life evaluation in Japanese pregnant women with striae gravidarum: A cross-sectional study. *BMC Res Notes* 2012;21:450.
- Burrows NP, Lovell CR. Disorders of connective tissue. In: Burns T, Breathnach S, Cox N, Griffiths C, editors. *Rook's Textbook of Dermatology*, 8th edition. Oxford: Wiley Blackwell; 2010. p 45.
- Elsaie ML, Baumann LS, Elsaieie LT. Striae distensae (stretch marks) and different modalities of therapy: An update. *Dermatol Surg* 2009;35:563–573.
- Al-Himdani S, Ud-Din S, Gilmore S, Bayat A. Striae distensae: A comprehensive review and evidence-based evaluation of prophylaxis and treatment. *Br J Dermatol* 2014;170:527–547.
- McDaniel DH. Laser therapy of stretch marks. *Dermatol Clin* 2002;20:67–76.
- Watson RE, Parry EJ, Humphries JD, et al. Fibrillin microfibrils are reduced in skin exhibiting striae distensae. *Br J Dermatol* 1998;138:931–937.
- Elson ML. Treatment of striae distensae with topical tretinoin. *J Dermatol Surg Oncol* 1990;16:267–270.
- Kang S, Kim KJ, Griffith CE, et al. Topical tretinoin (retinoic acid) improves early stretch marks. *Arch Dermatol* 1996;132:519–526.
- Young GL, Jewell D. Creams for preventing stretch marks in pregnancy. *Cochrane Library* 2008;1:1–7.
- Mallol J, Belda MA, Costa D, Noval A, Sola M. Prophylaxis of striae gravidarum with a topical formulation. A double blind trial. *Int J Cosm Sci* 1991;13:51–57.



11. Adatto MA, Deprez P. Striae treated by a novel combination treatment—Sand abrasion and a patent mixture containing 15% trichloroacetic acid followed by 6-24 hrs of a patent cream under plastic occlusion. *J Cosmet Dermatol* 2003;2:61–67.
12. Deprez P. Easy peel for the treatment of stretch marks. *Int J Cosmet Surg Aesthet Dermatol* 2000;2:201–204.
13. Karimipour DJ, Kang S, Johnson TM, et al. Microdermabrasion: A molecular analysis following a single treatment. *J Am Acad Dermatol* 2005;52:215–223.
14. Abdel-Latif AM, Albendary AS. Treatment of striae distensae with microdermabrasion: A clinical and molecular study. *J Egyptian Women Dermatol Soc* 2008;5:24–30.
15. Manuskiatti W, Boonthaweeyuwat E, Varothai S. Treatment of striae distensae with a TriPollar radiofrequency device: A pilot study. *J Dermatolog Treat* 2009;20:359–364.
16. Hernandez-Perez E, Colombo-Charrier E, Valencia-Ibieta E. Intense pulsed light in the treatment of striae distensae. *Dermatol Surg* 2002;28:1124–1130.
17. Al-Dhalimi MA, Abo Nasyria AA. A comparative study of the effectiveness of intense pulsed light wavelengths (650 nm vs 590 nm) in the treatment of striae distensae. *J Cosmet Laser Ther* 2013;15:120–125.
18. Park KY, Kim HK, Kim SE, Kim BJ, Kim MN. Treatment of striae distensae using needling therapy: A pilot study. *Dermatol Surg* 2012;38:1823–1828.
19. Aust MC, Fernandes D, Kolokythas P, Kaplan HM, Vogt PM. Percutaneous collagen induction therapy: An alternative treatment for scars, wrinkles, and skin laxity. *Plast Reconstr Surg* 2008;121:1421–1429.
20. Hague A, Bayat A. Therapeutic targets in the management of striae distensae: A systematic review. *J Am Acad Dermatol* 2017;77(3):559–568.e18.
21. Jimenez GP, Flores F, Berman B, Gunja-Smith Z. Treatment of striae rubra and striae alba with the 585-nm pulsed-dye laser. *Dermatol Surg* 2003;29:362–365.
22. Alexiades-Armenakas MR, Bernstein LJ, Friedman PM, Geronemus RG. The safety and efficacy of the 308-nm excimer laser for pigment correction of hypopigmented scars and striae alba. *Arch Dermatol* 2004;140:955–960.
23. Goldman A, Rossato F, Prati C. Stretch marks: Treatment using the 1064-nm Nd:YAG laser. *Dermatol Surg* 2008;34:686–692.
24. Longo L, Postiglione MG, Marangoni O, et al. Two-year follow-up results of copper bromide laser treatment of striae. *J Clin Laser Med Surg* 2003;21:157–160.
25. de Angelis F, Kolesnikova L, Renato F, Liguori G. Fractional nonablative 1540-nm laser treatment of striae distensae in Fitzpatrick skin types II to IV: Clinical and histological results. *Aesthet Surg J* 2011;31(4):411–419.
26. Wang K, Ross N, Osley K, Sahu J, Saedi N. Evaluation of a 1540-nm and a 1410-nm nonablative fractionated laser for the treatment of striae. *Dermatol Surg* 2016;42(2):225–231.
27. Stotland M, Chapas AM, Brightman L, et al. The safety and efficacy of fractional photothermolysis for the correction of striae distensae. *J Drugs Dermatol* 2008;7(9):857–861.
28. Guertler A, Reinholz M, Steckmeier S, Gauglitz GG. Evaluation of a non-ablative, fractional 1565 nm laser for the improvement of striae distensae albae. *J Eur Acad Dermatol Venereol* 2018. <https://doi.org/10.1111/jdv.15228>
29. Lee SE, Kim JH, Lee SJ, et al. Treatment of striae distensae using an ablative 1060-nm carbon dioxide fractional laser: A retrospective review of 27 participants. *Dermatol Surg* 2010;36:1683–1690.
30. Alster TS, Lupton JR. Prevention and treatment of side effects and complications of cutaneous laser resurfacing. *Plast Reconstr Surg* 2002;109:308–316.
31. Trelles MA, Khomchenko V, Alcolea JM, Martínez-Carpio PA. A novel method of facial rejuvenation using a 2,940-nm erbium:YAG laser with spatially modulated ablation: A pilot study. *Lasers Med Sci* 2016;31(7):1465–1471.
32. Alcolea JM, Hernández E, Martínez-Carpio PA, et al. Treatment of chronic lower extremity ulcers with a new Er:Yag laser technology. *Laser Ther* 2017;26(3):211–222.
33. Hersant B, SidAhmed-Mezi M, Chossat A, Meningaud JP. Multifractional microablative laser combined with spatially modulated ablative (SMA) technology for facial skin rejuvenation. *Lasers Surg Med* 2017;49(1):78–83.
34. Tay YK, Kwok C, Tan E. Non-ablative 1,450-nm diode laser treatment of striae distensae. *Lasers Surg Med* 2006;38(3):196–199.
35. Güngör S, Sayilgan T, Gökdemir G, Özcan D. Evaluation of an ablative and non-ablative laser procedure in the treatment of striae distensae. *Indian J Dermatol Venereol Leprol* 2014;80(5):409–412.
36. Adatto MA, Deprez P. Striae treated by a novel combination treatment—sand abrasion and a patent mixture containing 15% trichloroacetic acid followed by 6–24 hrs of a patent cream under plastic occlusion. *J Cosmet Dermatol* 2003;2(2):61–67.
37. van de Kar AL, Corion LU, Smeulders MJ, Draaijers LJ, van der Horst CM, van Zuijlen PP. Reliable and feasible evaluation of linear scars by the patient and observer scar assessment scale. *Plast Reconstr Surg* 2005;116(2):514–522.
38. Likert R. A technique for the measurement of attitudes. *Arch Psychol* 1932;140:1–55.
39. Elsaie ML, Baumann LS, Elsaie LT. Striae distensae (stretch marks) and different modalities of therapy: An update. *Dermatol Surg* 2009;35:563–573.
40. Stamatias GN, Lopes-DaCunha A, Nkengne A, Bertin C. Biophysical properties of striae distensae evaluated *in vivo* using non-invasive assays. *Skin Res Technol* 2015;21(2):254–258.
41. Aldahan AS, Shah VV, Mlacker S, Samarkandy S, Alsaidan M, Nouri K. Laser and light treatments for striae distensae: A comprehensive review of the literature. *Am J Clin Dermatol* 2016;17(3):239–256.
42. Wang K, Ross N, Osley K, Sahu J, Saedi N. Evaluation of a 1540-nm and a 1410-nm nonablative fractionated laser for the treatment of striae. *Dermatol Surg* 2016;42(2):225–231.
43. Tretti Clementini M, Lavagno R. A novel 1565 nm non-ablative fractional device for stretch marks: A preliminary report. *J Cosmet Laser Ther* 2015;17:148–155.
44. Gauglitz GG, Reinholz M, Kaudewitz P, et al. Treatment of striae distensae using an ablative Erbium:YAG fractional laser versus a 585-nm pulsed-dye laser. *J Cosmet Laser Ther* 2014;16:117–119.
45. Shen J, Lu XG, Jin JJ, Wang HW. Combination of a 2940 nm Er:YAG laser with recombinant bovine basic fibroblast growth factor (rb-bFGF) and light-emitting diode-red light (LED-RL) for the treatment of striae alba: A pilot study. *J Cosmet Dermatol* 2018;17(2):176–183.
46. Guida S, Galimberti MG, Bencini M, Pellacani G, Bencini PL. Treatment of striae distensae with non-ablative fractional laser: Clinical and *in vivo* microscopic documentation of treatment efficacy. *Lasers Med Sci* 2018;33(1):75–78.
47. Harmelin Y, Boineau D, Cardot-Leccia N, et al. Fractionated bipolar radiofrequency and bipolar radiofrequency potentiated by infrared light for treating striae: A prospective randomized, comparative trial with objective evaluation. *Lasers Surg Med* 2016;48(3):245–253.